

# RADIOGRAFEN

RADIOGRAF RÅDET | 46. ÅRGANG | NR. 08 | OKTOBER 2018

## VEJEN FRA DE LEVENDE TIL DE DØDE

HIC GAUDET MORS  
SUCCURRERE VITAE

PLUS  
▽

AMAGER-RADIOGRAF  
OPFINDER RØNTGENBUKS

MRI SAFETY IN COMMON  
DENTAL MATERIALS

RADIOGRAFISK  
FORÅR

# MRI SAFETY IN COMMON DENTAL MATERIALS

## – WHAT A RADIOGRAPHER NEEDS TO KNOW

Af | Finn Kristian Mathiesen<sup>1</sup>, Hanne Hintze<sup>2</sup> and Malene Roland Pedersen<sup>1, 3</sup>

1) Department of Radiology, Clinical Cancer Centre, Vejle hospital – Part of Lillebaelt Hospital, Vejle, Denmark

2) Specialist Clinic of Oral Surgery and Radiology, Aarhus, Denmark.

3) Institute of Regional Health Research, University of Southern Denmark, Odense, Denmark.

### CORRESPONDING AUTHOR:

Dr. Malene R. Pedersen  
Department of Radiology  
Vejle Hospital, Beriderbakken 4, 7100 Vejle  
Denmark, Fax: +45 7940 6873  
E-mail: Malene.Roland.Vils.Pedersen@rsyd.dk

### INTRODUCTION

Magnetic Resonance Imaging (MRI) has become a primary diagnostic tool for many clinical problems. It is often a concern that radiofrequency (RF) will cause heating of metallic objects in patients. Dental objects such as orthodontic brackets may cause substantial artefacts during imaging examination (1). Dental implants may be removed before an MRI examination because they are suspected to be MRI incompatible or will cause artefacts, especially in the head and neck region. Besides image artefacts and heating, risk of movement and dislodgement is also cause of concern. However, removing dental objects is time consuming, and may be painful and uncomfortable for the patient. Strong magnetic force may cause damage to dental objects or injury to the patients and in some cases it may be necessary to remove dental objects if they distort the magnetic field and affect the image quality. Furthermore, a heating effect may occur in the dental object due to the RF signal. As a consequence, implants are often removed or patients may be excluded from MRI examination.

Safety of metal objects has been moderately published (2–6) in papers and

on web pages (7). Still, safety remains a subject of debate in the daily clinical practice. Recently a study investigated heating in dental objects using a 7 tesla MRI scanner found that most metallic dental objects showed no apparent significant heating - only a mild temperature increase of up to 1.5 °C (8).

The aim of this study was to evaluate the thermal effect and risk of magnetic displacement force induced by a 1.5 T MRI in a broad range of commonly used dental objects.

### MATERIAL AND METHODS

#### MRI

A Phillips Achieva 1.5 Tesla MR scanner was used. Three fourths of the worlds MRI units have this field strength or lower. A 3 Tesla scanner was not available at the time of the study.

#### Metallic dental objects

A total of 21 different commonly used metallic dental objects were included. All objects were independently tested for magnetic displacement force and RF heating (Table 1), in order to identify which objects should be removed before an MRI examination.

#### Assessment of magnetic attraction

Translational attraction forces on the 21 dental objects were examined individually, by bringing each dental object slowly closer to the MRI magnet, and observe for any significant pull in the object. If the deflection angle was greater than 45°, then the material was defined to have a strong attraction force and could not be brought into the magnet (9). Weak magnetic force was observed by placing the objects in a small tray with durum flour and watch for any movement

of the dental object after bringing the tray in and out of the centre of the MRI magnet. Durum flour was used to visualize and measure how much movement each dental object performed.

#### Assessment of radiofrequency heating

Radiofrequency heating in dental objects was measured with a fibre optic probe thermometer (LumaSense™ Technologies, Frankfurt, Germany) attached directly to each dental object, during the MRI scans. All the dental objects were placed directly on a dry human finger bone specimen embedded in a large chicken breast phantom. The phantom was fixed, and placed in the head coil of the scanner (Figure 1). The phantom temperature was constant during the scans. All the dental objects were subjected to two MRI sequences. The total scan time for each dental object was 13 minutes and 43 seconds.

#### Choice of MRI sequences

A T2-weighted Turbo Spin Echo (TSE) sequences with a high Specific Absorption Rate (SAR) was selected to produce tissue heating (TR/TE 3000/120 ms,

**TABLE 1. THE MRI EXAMINATION PROTOCOL**

	T2W_TSE	B_FFE*
TR/TE	3000/120 ms	9.7/4.9 ms
Scan time	5.27 minuts	8.16 minuts
SAR	<3.4 W/Kg	1.3 W/Kg
Flip angle	NR	50°

\*B\_FFE sequence uses a balanced gradient waveform that starts with a RF puls of 90° or less and spins in steady state. The flip angle is used to define the angle of excitation for the field echo puls sequence.

Abbreviations: TR= time to repetition; TE = time to echo; SAR =The Specific Absorption Rate; NR = not relevant.

scan time 5.27 min, SAR < 3.4 W/Kg) and a Balanced Fast Field Echo (B\_FFE) was selected as a sequence capable of induction of current in a metal object (TR/TE 9.7/4.9 ms, flip angel 50°, scan time 8.16 min, SAR 1.3 W/Kg).

## RESULTS

All the examined dental objects are visualized in Figure 2 and 3, and further detail are listed in table 1.

Two of the dental objects had a strong magnetic attraction (deflection angle > 450) and could not be brought into the magnet. As a result no MRI examination was performed on dental object no. 1 and object no. 20.

A total of three metallic dental objects had a weak magnetic attraction force as they showed physical movement in the flour tray, when bringing the tray in and out of the magnet (dental object no. 13, 16, and 21). The after situation indicated by a pen on the tray (Figure 4).

A semicircle steel orthodontic bracket wire (dental object no. 21) showed a temperature increase of 0.8 °C.

A total of 4 dental objects had no temperature change during the MRI scans. However, in 14 dental objects a slight decrease in the temperature occurred most likely due to the cooling fan in the scanner that could not be completely disabled.

In dental object no. 21, which had a temperature increase of 0.8 °C, we performed a number of additional B\_FFE sequences in order to examine if the temperature would increase further. After the third additional sequence the temperature stabilized at an increase of maximum 1.4°C, with a total scan time of 38 minutes and 31 seconds.

## DISCUSSION

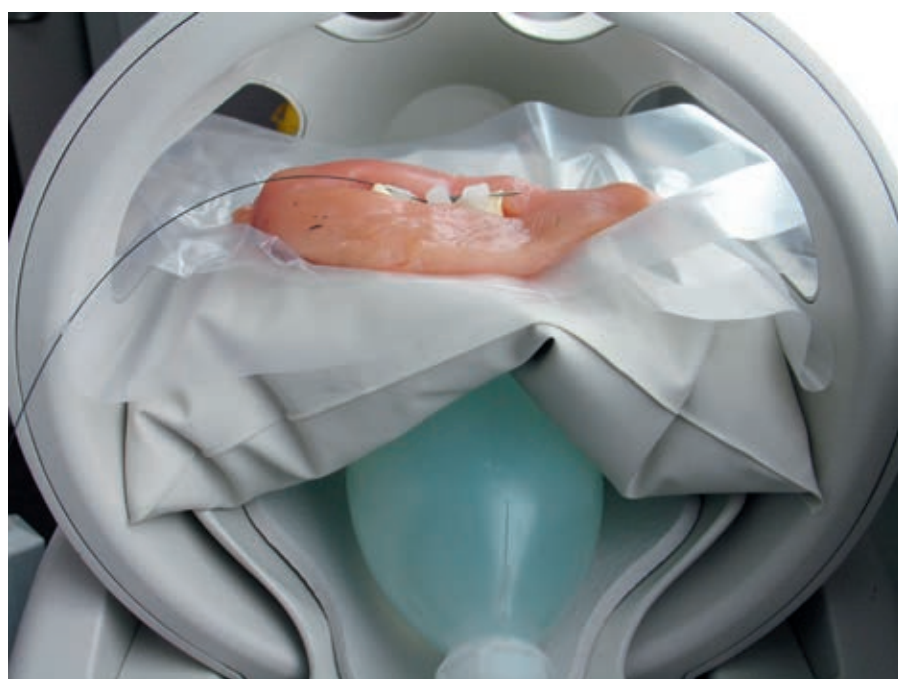Safety assessment of common dental objects is necessary before patients safely can undergo an MRI examination. In this study commonly used dental objects were systematically examined with two different MRI sequences. Often patients with a metallic object in the oral cavity, especially those re-

ferred for a head or neck MRI examination, will not be allowed to undergo MRI examination, before the object has been temporarily removed for safety reasons. This is a very time-consuming and expensive procedure, and often the examination will be delayed. In this study, the most common dental objects did not cause safety problems, and therefore can be left in situ during MRI examination. This finding is consistent with similar findings using both 7T and 3T (6,8,10-12).

The steel orthodontic wire (object no. 21), formed as a semicircle, showed temperature increase during the first scanning sequence with 0.8°C, and obtained a maximum temperature increase of 1.4°C after three additional scans. Theoretically, semicircular objects are cause of concern because they are induction coils and predisposed for temperature increase during MRI gradient changes. However, a maximum temperature increase of 1.4°C is within the daily fluctuation in body temperature, and therefore such dental objects does not need to be removed before a MRI due to heating. Other studies have also found that dental objects commonly used, does not result in any hazardous risk to the patient due to heating (11,13).

The value of MRI related heating is measured as the average specific absorption rate (SAR) per weight unit in the whole body and is normally used for safety reporting of clinical MRI procedures. But the SAR may not be such a good measurement, because it is a biologically tissue-heating index omitted metallic implants. Furthermore, each MRI system calculates the SAR differently (14,15). Eriksson and Albrektsson reported from an animal study that exposed for temperatures of 44-47 °C (7-10 °C above normal body temperature) is able to cause alveolar bone necrosis (16). Studies from Hasegawa, Görgülü et al all found minor temperature rise during MRI in metallic objects (3,6,11). We found no hazard temperature rising.

An additional safety concern is the possibility of dental objects movement or displacement due to the magnetic field strength. The extent of the interaction between the metallic object and the static magnetic field is proportional with the strength of the MRI system and characteristics of the object (mass, shape and magnetic strength of the object). According to the American Society for Testing and Materials (ASTM) international standard, a metallic object deflection angle of no greater than 450 is stated to be considered safe in terms



Shows the chicken breast phantom with a dental object placed directly on a dry human finger bone specimen. The phantom was fixed, and placed in the head coil of the scanner.


of attraction by static magnetic field as the magnetically deflection force is less than the force on the object caused by gravity (9). We found two dental objects, a Palladium alloy and a steel Herbst appliance, to be highly magnetic with a deflection angle greater 450, and no MRI was performed on these. One should always consider possible tissue damage, if a dental object can move or dislodge.

We found three objects with a weak subtle attraction force. Usually these dental objects would be firmly cemented or fixed to a prosthesis, which is firmly fixed to teeth or tooth roots, and the dental cement would be strong enough to prohibit any movement

Shows metallic dental objects before and after they had been placed in the centre of the MRI scanner. Notice three dental objects had a weak magnetic attraction force, as they showed physical movement in the flour tray (dental object no. 13, 16, and 21).

Therefore all of the objects with a deflection angle less than 450 can safely undergo an MRI examination.

A limitation of this study was that the RF heating was measured in a phantom, and not directly in vivo e.g. a human mouth. However, the phantoms tissue and bone was equivalent with the jaw. The study was performed using a 1.5 Tesla as it is



**TABEL 2. INFORMATION ON THE 21 DENTAL IMPLANTS AND THEIR MAGNETIC FORCE INCLUDING DECREASE OR INCREASE IN TEMPERATURE AFTER THE T2W\_TSE AND B\_FFE**

NO.	TRADEL NAME (MATERIAL)	MANUFACTOR	COMPOSITION	MAGNETIC DISPLACE- MENT	BASE- LINE	TSE	B_FFE	TOTAL DIFF
1	DYNA EFM Alloy	DYNA DENTAL ENGINEERING BV	60% palladium, 36.8% cobalt, 1% platinum, 2.2% other	Strong	NR	NR	NR	NR
2	Wirobond®C	BEGO Bremer Goldschlaegerei, Bremen, Germany	63.3% cobalt, 24.8% chromium, 5.1% molybdenum, 5.3% wolfram	None	23.5	22.9	22.1	- 1.4
3	Machined Implant	Branemark® Nobel Biocare, Zürich, Switzerland	Pure grade 4 unalloyed titanium (CP-4)	None	22.1	21.6	21.4	-0.7
4	Abutment and screw	Branemark® Nobel Biocare, Zürich, Switzerland	90% titanium, 6% aluminium, 4% vanadium	None	21.9	21.1	21.1	-0,8
5	TiUnite Implant	Nobel Biocare®, Zürich, Switzerland	Pure grade 1 unalloyed titanium (CP-1)	None	20.9	20.4	20.4	- 0.5
6	Titanium Abutment	Nobel Biocare®, Zürich, Switzerland	90% titanium, 6% aluminium, 4% vanadium	None	21.0	20.7	20.5	-0.5
7	Internal metallic fixation	Biomet® Microfixation, Jacksonville, Florida, USA	Pure titanium	None	20.7	20.4	20.3	-0,4
8	Fixation cross-drive screw	Biomet® Microfixation, Jacksonville, Florida, USA	Pure titanium	None	21.7	20.3	20.2	-1.5
9	Ligature wire	Remanium® Dentaaurum, Ispringen, Germany	Stainless steel (est. 70% Iron, 18% chrome, 10% nickel)	None	21.2	20.3	20.2	-1.0
10	Poly J jaw Plate	Dansk Edelmetal A/S, Farum, Denmark	Stainless steel (est. 70% Iron, 18% chrome, 10% nickel)	None	20.7	20.1	20.2	-0,5
11	Aluminium cap	M+W Dental, Büdingen, Germany	99,5% aluminium	None	21.4	21.3	21.3	-0.1
12	Bonding brackets	Ultramintrim® Dentaaurum, Ispringen, Germany	Stainless steel (est. 70% Iron, 18% chrome, 10% nickel)	None	21.9	22.0	21.9	0.0
13	Reamer Bioline 4C27A	Dentatus AB, Spånga, Sweden	Hardened stainless steel (est. 70% Iron, 18% chrome, 10% nickel)	Weak	20.9	20.7	20.6	-0.3
14	Dentatus surtex root pin	Dentatus AB, Spånga, Sweden	Pure grade 1 unalloyed titanium	None	20.9	20.5	20.4	-0,5
15	Para-pulpal MAX® 021 pin	Coltène Whaledent Inc., JT, USA	90% titanium, 6% aluminium, 4% vanadium	None	20.9	20.8	20.9	0.0
16	K-flex 45 file	Kerr, Scafati, Italy	70% iron, 19% chromium, 9% nickel, 1% magnesium	Weak	21.3	21.3	21.3	0.0
17	Root canal file F3	Protaper®, Densply, Ballaigues, Switzerland	55% nickel, 45% titanium	None	21.6	21.5	21.5	-0.1
18	Aarhus anchorage screw	Medicon Instrumente, Tuttlingen, Germany	90% titanium, 6% aluminium, 4% vanadium	None	21.8	21.7	21.8	0.0
19	Lingual retainer wire	Reliance Orthodontic Products Inc., Itasca, IL, USA	Stainless steel (est. 70% Iron, 18% chrome, 10% nickel)	None	21.9	21.8	21.8	-0.1
20	Herbst appliance IV-set	Herbst® Dentaaurum, Ispringen, Germany	Stainless steel (est. 70% Iron, 18% chrome, 10% nickel)	Strong	NR	NR	NR	NR
21	Orthos preformed archwire	Ormco, Glendora, California, USA	Stainless steel (est. 70% Iron, 18% chrome, 10% nickel)	Weak	19.9	20.2	20.7	0.8

NR= Not reported because the magnet pull was to strong to perform the two MRI scans

the most common field strength worldwide. Dental objects that are MRI safe at 1.5 T, may not be safe in a 3.0 T.

A strength of this study is the focus on MRI safety, and the high number of commonly used dental objects, which may be helpful to clinicians and orthodontist. However metallic objects will cause artefacts and in some situations dental objects may still have to be removed.

## CONCLUSION

Not all dental objects are MRI safe, however the majority of the tested metallic dental objects were MRI safe, and showed no magnet attraction or temperature heating. In general dental objects do not need to be removed before an MRI examination due to RF induced heating. Decision to remove dental objects should be made based on the objects composition and the risk of clinically relevant image artefact (17).

## REFERENCE

1. Pauchard M, Smith M, Mintchev M. Improving geometric accuracy in the presence of susceptibility difference artifacts produced by metallic implants in magnetic resonance imaging. *IEEE Trans Med Imaging*. 2005;24(10):1387-99.
2. Shellock FG. Metallic neurosurgical implants: Evaluation of magnetic field interactions, heating, and artifacts at 1.5-Tesla. *J Magn Reson Imaging*. 2001;14(3):295-9.
3. Shellock FG, Crues J V. MR procedures: biological effects, safety, and patient care. *Radiology*. 2004;232(3):635-52.
4. Klocke A, Kemper J, Schulze D, Adam G, Kahl-Nieke B. Magnetic field interactions of orthodontic wires during magnetic resonance imaging (MRI) at 1.5 Tesla. *J Orofac Orthop*. 2005;66(4):279-87.
5. Beau A, Bossard D, Gebeile-Chauty S. Magnetic resonance imaging artefacts and fixed orthodontic attachments. *Eur J Orthod*. 2015;37:105-10.
6. Hasegawa M, Miyata K, Abe Y, Ishigami T. Radiofrequency heating of metallic dental devices during 3.0 T MRI. *Dentomaxillofac Radiol*. 2013;42(5):20120234.
7. MRI safety.com [Internet]. Visit on the 1st of february 2017. Available from: <http://www.mrisafety.com>
8. Oriso K, Kobayashi T, Sasaki M, Uwano I, Kihara H, Kondo H. Impact of static and radiofrequency magnetic fields produced by a 7T MR imager on metallic dental materials. *Magn Reson Med Sci*. 2016;15(1):26-33.
9. American Society for Testing and Materials (ASTM) International. Standard test method for measurement of magnetically induced displacement force on passive implants in the magnetic resonance environment. West Conshohocken. PA. 2006: F2052-06.
10. Miyata K, Hasegawa M, Abe Y, Tabuchi T, Namiki T, Ishigami T. Radiofrequency heating and magnetically induced displacement of dental magnetic attachments during 3.0 T MRI. *Dentomaxillofac Radiology*. 2012;41(8):668-74.
11. Görgülü S, Ayyıldız S, Kamburo lu K, Gökçe S, Ozen T. Effect of orthodontic brackets and different wires on radiofrequency heating and magnetic field interactions during 3-T MRI. *Dentomaxillofac Radiology*. 2014;43(2):20130356.
12. Regier M, Kemper J, Kaul MG, Feddersen M, Adam G, Kahl-Nieke B, et al. Radiofrequency-induced heating near fixed orthodontic appliances in high field MR systems at 3.0 Tesla. *Journal of Orofacial Orthopedics*. 2009;70:485-94.
13. Ayyıldız S, Kamburo lu K, Sipahi C, Murat S, Görgülü S, Piskin B. Radiofrequency heating and magnetic field interactions of fixed partial dentures during 3-tesla magnetic resonance imaging. *Oral Surg Oral Med Oral Pathol Oral Radiol*. 2013;116(5):640-7.
14. Baker KB, Tkach JA, Nyenhuis JA, Phillips M, Shellock FG, Gonzalez-Martinez J, et al. Evaluation of specific absorption rate as a dosimeter of MRI-related implant heating. *J Magn Reson Imaging*. 2004;20(2):315-20.
15. Baker KB, Nyenhuis JA, Hrdlicka G, Rezai AR, Tkach JA, Shellock FG. Neurostimulation systems: Assessment of magnetic field interactions associated with 1.5- and 3-Tesla MR systems. *J Magn Reson Imaging*. 2005;21(1):72-7.
16. Eriksson A, Albrektsson T. Temperature threshold levels for heat induced bone tissue injury: a vital-microscopy study in the rabbit. *J Prosthet Dent*. 1983;50(1):101-7.
17. Poorsattar-Bejeh Mir A, Rahmati-Kamel M. Should the orthodontic brackets always be removed prior to magnetic resonance imaging (MRI). *J Oral Biol Craniofac Res*. 2016;6:142-52.



**Et forsikringsfællesskab for dig,  
der kan se lige igennem folk.**

Bauta Forsikring er et forsikringsfællesskab for udvalgte faggrupper, blandt andre radiografer. Vi er ejet af vores medlemmer med alle de fordele, der følger med.

Vores mål er at sikre dig den lavest mulige pris og den højest mulige erstatning.

Tjener vi for meget på en forsikring, kommer det også dig til gode, enten ved at vi sænker priserne eller forbedrer dine forsikringer.

Derudover belønner vi dig årligt med en rabat på dine forsikringer, når du har været medlem i tre år.

Hvis du kan se meningen, så se, hvordan du bliver medlem.

**Gå ind på [bauta.dk/blivmedlem](http://bauta.dk/blivmedlem) eller ring til os på 33 95 76 81.**



Vores forsikringer er gang på gang kåret  
Bedst i test af Forbrugerrådets magasin  
Tænk Penge.  
Senest for vores indboforsikring.

Bauta Forsikring – en del af LB Forsikring  
A/S, CVR-nr. 16 50 08 36,  
Farvergade 17, 1463 København K

  
**Bauta Forsikring**  
En del af LB Forsikring